

WISSENSCHAFTLICHE KURZMITTEILUNGEN

**Diphyodont dentition of first premolar in the Red fox  
*Vulpes vulpes* (Linné, 1758)**

By H. ANSORGE

*Staatliches Museum für Naturkunde Görlitz, FRG*

*Receipt of Ms. 11. 12. 1989  
Acceptance of Ms. 26. 1. 1991*

The diphyodont dentition of mammals shows different modifications in several orders. Within the carnivores, it is especially remarkable for Canidae and Mustelidae that the first (orally situated) premolar appears only once and is not changed like the other premolars.

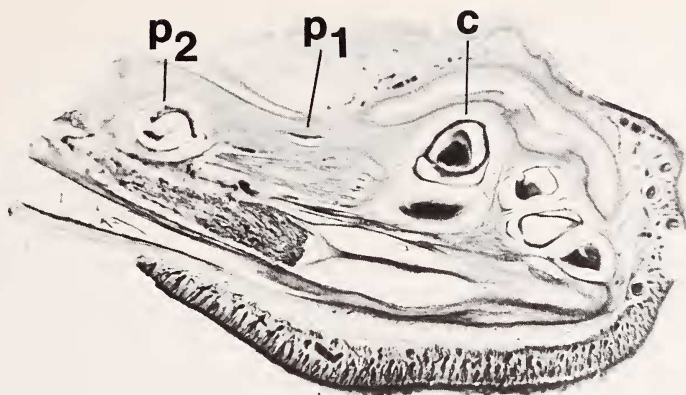
Thus, the first premolars are not generated in the short tooth row of the fox puppy, but appear not earlier than after 15 to 16 weeks. There is much controversy to which of the two types of dentitions this first premolar belongs. SLAUGHTER et al. (1974) treat the "unreplaced DP1/dp1" as teeth of the milk dentition. SEIFERLE and MEYER (1942) also interpret the P1 as a late emerging and persisting milk tooth, being equivalent to a permanent tooth in size and form. However, LÜPS et al. (1972) emphasize that the P1 is developed only in one generation as a typical permanent tooth and cannot be a persisting milk tooth. Concerning the Red fox, CAPT et al. (1980) emphasize the P1 to be the earliest permanent tooth which is not established in milk dentition. Supporting this assumption HOCHSTRASSER (1971) found supernumerary first premolars in the red fox and regarded it as an exceptionally developed and persisting milk tooth. Such persisting milk teeth are also known in primates (KRAPP and LAMPEL 1973). Accepting ontogenetic dental development as embryonic recapitulation of phylogeny (GÄNGLER 1987), it seems likely that a milk-tooth bud developed prior to the emergence of P1 from the secondary dental lamina.

To resolve this problem, the lower jaws of differently aged Red foxes were studied: embryos of 37, 40, 43, 45 and more than 50 days originating from wild vixens as well as 2-week-old puppies from artificial rearings. The age of embryos was estimated according to LAYNE and MCKEON (1956). Series of sagittal sections of paraffin-embedded jaws enabled the identification of dental cups.

The 37-day-old embryo possesses already well-differentiated dental cups of canines and incisors. Alterations in jaw structure suggest future emergence of two premolars.

The lower jaw of the 40-day-old embryo shows all dental cups of the complete deciduous dentition. Almost equidistant from  $p_2$  and canine cups, a small lenticular tissue structure is situated in a bone loosening at the same horizontal level. This structure must be regarded as  $p_1$  bud as investigation of older embryos showed. This dental bud appears unchanged in the serial sections of the 43-day-old embryo, whereas the other dental cups experienced further size growth and differentiation (Fig.).

The dental cup of  $p_1$  does not change during the further embryogenesis. In the lower jaw of most developed fetuses it is clearly recognized and situated dorsal to the proximal end of the canine, directed skewly anteriorly. It has only slightly increased (0.37 mm diameter) but shows no further differentiation. Therefore, this indicates a rudimentary tooth bud. At the same time, the canine, for example, already shows a typical tooth appearance.



Sagittal section of the red fox lower jaw (43-day-old embryo)

In sections of the 2-week-old fox puppy the dental bud of permanent  $P_1$  is clearly perceptible, beside the  $M_1$  germ. It is situated far buccal in the jaw. The deciduous  $p_1$  tooth bud of the older embryos placed lingually between canine and second premolar has dissolved. It cannot be identical with this permanent tooth bud.

Therefore, the first premolar appears in the deciduous dentition of the red fox at about the 40th embryonic day. This tooth shows no further differentiation and remains in the jaw as a rudimentary tooth bud. It dissolves in the first two weeks after birth. Thus, the red fox shows a complete diphyodont dentition by secondary suppression of the first premolar.

### Literature

- CAPT, S.; LÜPS, P.; FÜHRER, W. (1980): Zur Größen- und Längenvariation des  $P^1$  beim Rotfuchs *Vulpes vulpes*. Kleine Mitt. Naturhist. Mus. Bern Nr. 10, 1–5.
- GÄNGLER, P. (1987): Klinik der Konservierenden Stomatologie. Berlin: Verlag Volk u. Gesundheit.
- HOCHSTRASSER, G. (1971): Die Zahnzahl des Rotfuchses, *Canis vulpes* (Linné, 1758), im Vergleich mit der anderen Caniden. Säugetierkd. Mitt. 19, 194–198.
- KRAPP, F.; LAMPEL, G. (1973): Zahnanomalien bei Altweltaffen (Catarrhinae). Rev. Suisse Zool. 80, 83–150.
- LAYNE, J. N.; McKEON, W. H. (1956): Notes on the development of the Red fox fetus. New York Fish Game J. 3, 120–128.
- LÜPS, P.; NEUENSCHWANDER, A.; WANDELER, A. (1972): Gebißentwicklung und Gebißanomalien bei Füchsen (*Vulpes vulpes* L.) aus dem schweizerischen Mittelland. Rev. Suisse Zool. 79, 1090–1103.
- SEIFERLE, E.; MEYER, L. (1942): Das Normalgebiß des Deutschen Schäferhundes in den verschiedenen Altersstufen. Vierteljahrsschr. Nat. Ges. Zürich 87, 205–252.
- SLAUGHTER, B. H.; PINE, R. H.; PINE, N. E. (1974): Eruption of cheek teeth in Insectivora and Carnivora. J. Mammalogy 55, 115–125.

*Author's address:* Dr. HERMANN ANSORGE, Staatliches Museum für Naturkunde Görlitz, Forschungsstelle, PF 425, O-8900 Görlitz, Bundesrepublik Deutschland